

Effects of the Paraquat Herbicide on Oogenesis and Ovary Structure of Wistar Rat strain**¹Vahid HamayAtkhah, ²Mahmood Najafiyan, ³Mohammad Farzam, ⁴Hossin Kargar**¹*Department of biology islamic azad university, jahrom brunch, jahrom, iran*²*Department Of Chimistry Islamic Azad University, Jahrom Brunch, Jahrom, Iran*³*Department Of Biology Islamic Azad University, Jahrom Brunch, Jahrom, Iran*⁴*Department Of Biology Islamic Azad University, Jahrom Brunch, Jahrom, Iran*

Vahid HamayAtkhah, Mahmood Najafiyan, Mohammad Farzam, Hossin Kargar: Effects of the Paraquat Herbicide on Oogenesis and Ovary Structure of Wistar Rat strain

ABSTRACT

Paraquat is a herbicide with Gromoxone brand name. Paraquat is a dark green herbicide, with a liquid formulation which is used as a general contact poison in non-agricultural lands, side roads, orchards and fallow lands, to control all one year broadleaf and narrow leaf weeds effectively. After preparation, Gromoxone is highly poisonous and can be absorbed through skin. In this experiment 50 adult female Wistar rats, each weighing 200 ± 15 grams and three months old, were divided in to 5 groups of 10 specimens, including sham, control, experimental 1, experimental 2, experimental 3 groups. To study the effect of Paraquat as an herbicide on ovary structure and oogenesis of adult rat, initially the standard LD50 (8 mg / kg BW) was determined by injecting intraperitoneally. Then physiological serum was used as solvent. Then the sub lethal dose (4 mg / kg BW) and half of that dose (medium dose) (2 mg / kg BW) and the minimum dose (1 mg / kg. BW) was injected intraperitoneally once a day, for 14 days. Then the animals were dissected, blood samples were taken, and the ovaries were weighted, and then ovaries were studied macroscopically and microscopically. 5 micron serial sections of ovaries were prepared and were stained with Hematoxylin and Eosin, and the color results were analyzed statistically. In experimental groups, compared with control groups, a significant alternation in ovarian weight and blood levels of LH and FSH was observed. But significant decrease in the number of primordial, primary and growing follicles, the corpus luteum and its cells and the diameter of Graafian follicles and their oocytes and nuclei, theca and granulosa layers and also the diameter of the corpus luteum and the blood levels of estrogen and progesterin were observed. In the number of Graafian and atretic follicles and ovarian diameter, significant increase was observed. As such, based on the foregoing observations it can be concluded that Paraquat treatments for 14 days, can affect ovarian tissues and as a result the oogenesis process in rats.

Key words: Paraquat Herbicide ,Oogenesis ,Ovary Structure ,Wistar Rat strain**Introduction**

Because of its unique characteristics, Paraquat is consumed and produced significantly all over the world as a very strong herbicide. [1] Its chemical formula N^1,N Paraquat – dimethyl 4,4 dipyridine is used mainly as an herbicide. This herbicide is highly toxic to humans and animals (especially with the delay mechanism for humans). [2] These free radicals are highly toxic and strongly synthesize with macromolecules and may cause serious damages in various organs. Paraquat is used in rice, sugar cane, tobacco, and potatoes fields, fruit orchards, vineyards, etc. to control weeds. Agricultural pesticides are the most destructive biological contaminants. [3] The toxicity mechanism of Paraquat is often associated with the production of superoxide ethion that can lead to produce large

amounts of the oxygen species (ROS) such as hydrogen peroxide and superoxide ethion. These two free radicals are considered as two major toxicants. [4] Paraquat is known as a strong fetal toxic composition which effects amphibians' growth and development. Paraquat intoxication can cause drastic changes in fetus lungs which may lead to fibrosis. [5] These harmful effects which also happen in liver and kidneys, are caused by free radicals produced by Paraquat. [6] Systematic Paraquat injection in brain can have narcotic effects on rat's nerves. [7] Sever Paraquat intoxication can affect the rats' liver superstructure. [8] Treatment of male rats with Paraquat reduces the number of fetal cells in Balb/B rat strains and the shrinkage is considerable. [9] Thus, regarding the harmful effects of this substance in various body organs of animals, extensive researches are needed. The purpose of this research is

Corresponding AuthorVahid HamayAtkhah, Department of biology islamic azad university, jahrom brunch, jahrom, iran
E-mail: dr.hemayatkhah@yahoo.com

to study the effects of Paraquat herbicide on ovarian changes and oogenesis process, ovary structure, oocytes status and its nucleus, granulosa layers, and corpus luteum.

Materials and Methods

In this study adult Wistar rats (about 95 to 125 days) were purchased from Razy Institute of Vaccine and Serum Research in Shiraz. Rats were kept at animal breeding room in optimum temperature (22 ± 1 °C). Experimental rats were divided into control, sham and experimental groups each containing 6 specimens. In this study, lethal dose was determined as 8 mg/kg BW by injecting intraperitoneally. Then the sub lethal dose of 4 mg/kg BW and an average dose of 2mg/kg BW and minimum dose of 1 mg / kg BW were injected intraperitoneally for 14 consecutive days (once a day). In all experiments, water was used as solvent. The same volume of solvent was injected intraperitoneally to the sham groups. The control group received no injection. 15 days after the first injection, rats were dissected and the blood samples were collected from their hearts, then ovaries were removed. Blood serum was extracted and the hormone measurements were conducted at the Institute of Medical Sciences in Shiraz using the radioimmunoassay (RIA) technique. Ovarian weight was measured using a digital scale. Samples were fixed in Bowen fixator, then the process of dehydration, dealcoholization, paraffin penetration, and finally the molding was carried out. Then using microtome, 5 micron serial sections of ovaries were prepared and stained with Hematoxylin and Eosin. (Figure 1) An objective at 2/3 × magnification was used to Measure the ovarian diameter and an objective at 10 × magnification was used to count the follicles and corpus luteum Graafian. To count the number of primordial,

primary, growing and atretic follicles, an objective at 40 × magnification was used.

Granulosa and theca layer thickness in Graafian follicle, corpus luteum and oocytes diameter in Graafian follicle was measured with a graded ocular ruler (graded graticule). Corpus luteum cells were counted by an objective at 100 × magnification and a reticular ocular ruler (reticular graticule). Then the results were analyzed statistically using SPSS software, and graphs were plotted using Excel software.

Results:

The results are based on statistical methods. As Graphs 1-a and 2 (a and b) show, ovarian weight, FSH and LH hormone levels, in experimental groups altered significantly compared with control groups. Ovarian diameter in the experimental group increased significantly compared with the control group (05/0 > P) and also the number of Graafian follicles and atretic follicles also increased significantly (01/0 > P). (Figures 1 b and 3). The number of primordial follicles, the corpus luteum (Figure 3) granulosa layer thickness (Figure 4 and Figure 2) and progesterone hormone levels (Figure 2 c) in the experimental group decreased significantly (001 / > P) compared to the control group. The Graafian follicle diameter, the theca layer thickness (Figure 4) and estrogen levels (Figure 2 d) in the experimental group decreased significantly (01/0 < P), compared with control groups. Also the number of primary follicles, growing follicles, corpus luteum cells (Figure 3) and the oocyte diameter of Graafian follicles and their nuclei and also corpus luteum diameter (Figure 4) reduced significantly (05/0 > P) in the experimental groups, compared with control groups.

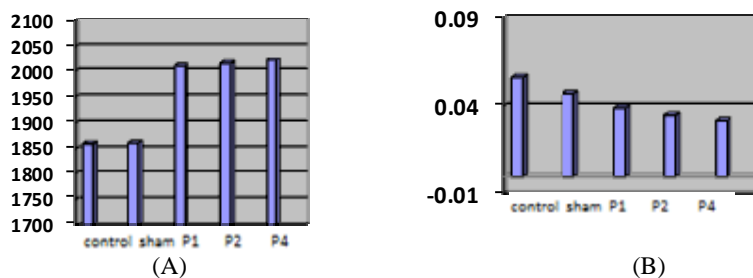


Fig. 1: (A) Comparison of ovarian weight in the three control, sham and experimental groups (7-day treatment with Paraquat) the observed reduction in ovarian weight in the experimental groups is not significant in compare with control groups. (B) The ovary diameter comparison in the control, sham and experimental groups (7-day treatment with Paraquat) shows a significant ($P < 0.05$) ovary diameter increase in experimental group, compared with control group.

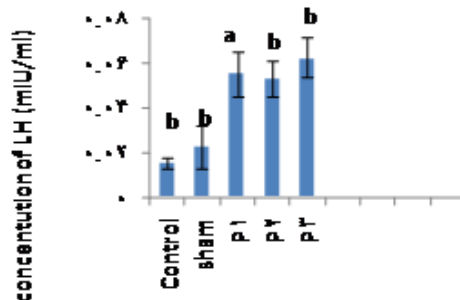


Fig. 1: Effect of Paraquat Herbicide on LH Hormone Concentration

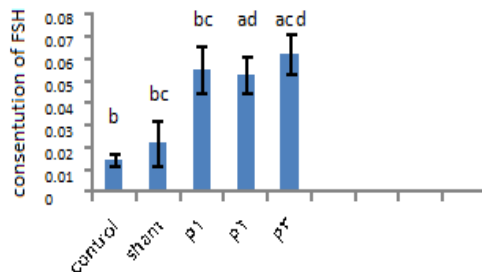


Fig. 2: Effect of Paraquat Herbicide on FSH Hormone Concentration

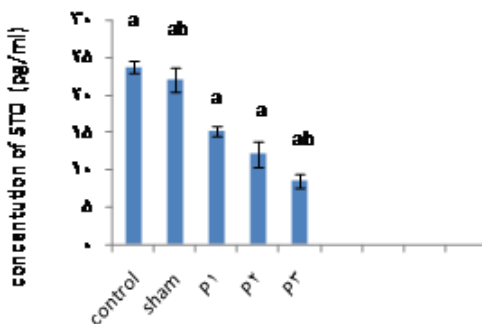


Fig. 3: Effect of Paraquat on Estrogen Hormone Concentration

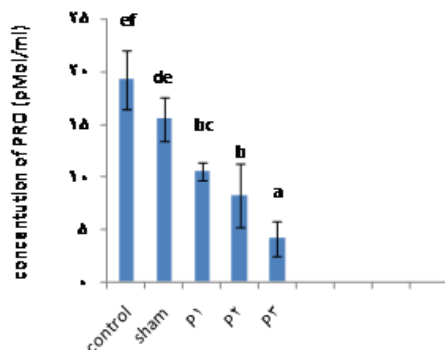


Fig. 4: Effect of Paraquat on Progesterone Hormone Concentration

Fig. 2: Comparing FSH (a) LH (b), progesterone (c) and ER (d) hormone levels of blood serum in control, sham and experimental (7-days treatment with Paraquat) groups. In each case the significant change (decrease) in experimental group, compared with control group is marked with a star ($P < 0.01$ ** and $P < 0.001$ ***). (a and b) The observed reduction is significant. (c and d) Shows a significant reduction in these hormones in experimental group, compared with control group.

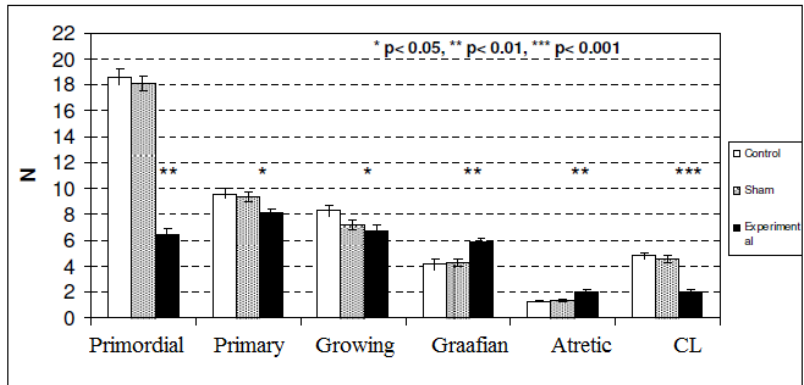


Fig. 3: Compares the number of primordial, primary, growing, Graafian, and atretic follicles and also the number of corpus luteum in the control, sham and experimental (7-day treatment with Paraquat) groups. In each case significant changes (increase or decrease) in the experimental group compared with control group is marked with stars (***) $P < 0.01$ ** $P < 0.05$ * $P < 0.001$)

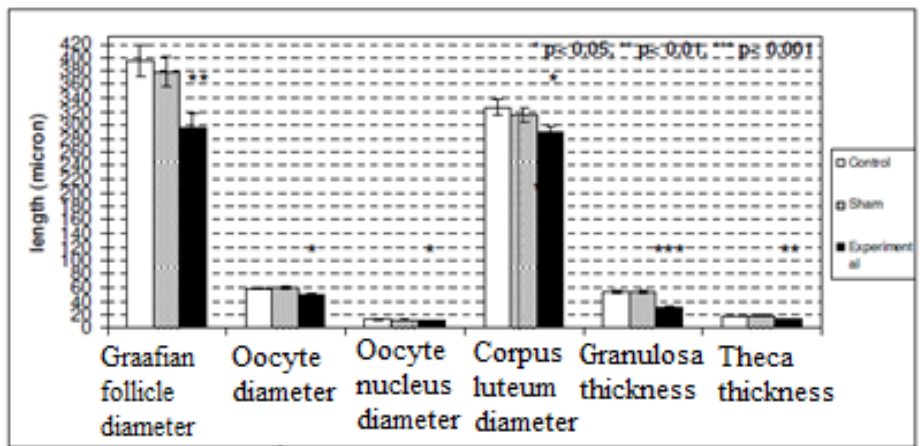
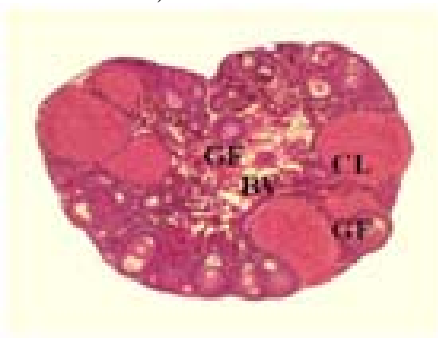
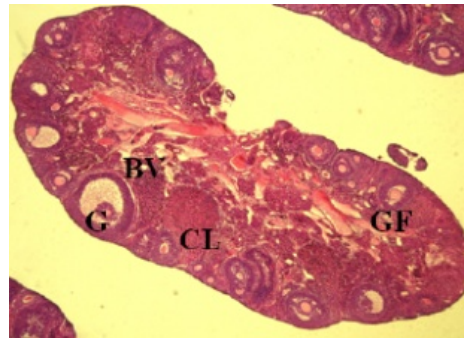


Fig. 4: Compares the Graafian follicle diameter, Graafian follicle oocyte, oocyte nucleus and corpus luteum and granulosa and theca layer thickness in Graafian follicle, in the control, sham and experimental (7-day treatment with Paraquat 20% EC) groups. In each case, the significant reduced (in diameter or thickness) in the experimental group compared with controls is marked with stars ($P < 0.001$ ***, $P < 0.01$ **, $P < 0.05$ *)



(A)



(B)

Fig. 1: (A) The micro-graph transect of ovary in control group. (B) The micro-graph transverse section of ovary in experimental group (7-day treatment with Paraquat 20% EC). Both samples are stained using Hematoxylin and Eosin.

GF: growing follicles; CL: corpus luteum BV: blood vessel; G: Graffian follicle. (125 ×Magnification)

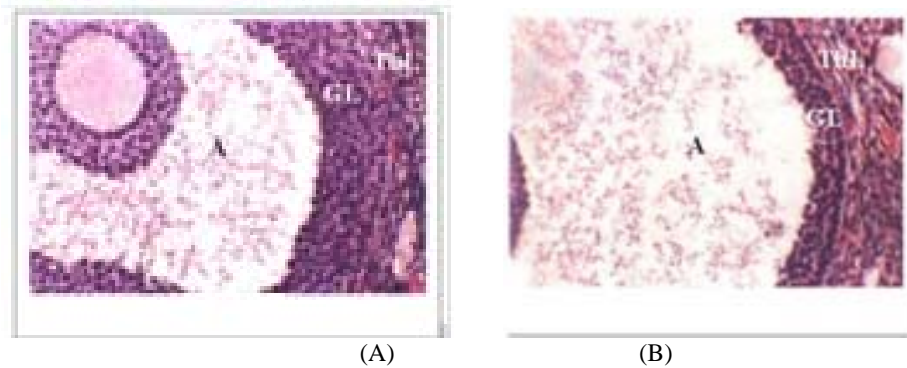


Fig. 2: (A) The micro-graph transverse section of Graffian follicle in control group. (B) The micro-graph transect of Graffian follicle in experimental group (under 7-day treatment with Paraquat 20% EC). Both samples are stained with Hematoxylin - Eosin. Reduction in granulosa and theca layers thickness in experimental group compared with control group is obvious.

A: Graffian follicle antrum; G1: granulosa layer; TH1: theca layer. (500 × Magnification)

Debate and interpretation:

So far, many studies on the effect of various doses of herbicides, on different organs in different animals have been done and each had used different sources. Therefore, the results obtained in this study about Paraquat effects on rat ovaries, can complete the present data on the effects of herbicides in different species which were studied previously.

The slight increase in ovarian diameter in experimental groups compared with control groups could be due to increased number of ovarian Graafian follicles and as a result the increase of ovarian volume in this group.

The fact that the ovarian diameter increase did not lead to significant increase in weight, can indicate that probably in experimental groups, after treatment with Paraquat, part of ovarian structure (Or of ovarian tissue or follicle and germ cells in ovary) is depleted. Confirm this, is the observed significant reductions in the number of follicles (except Graafian follicle), follicle volume and number and volume of the corpus luteum. Herbicides oxidative stress plays an important role in various pathogenesis diseases such as cancer, diabetes, cardiovascular disease, Parkinson's, schizophrenia, Atherosclerosis, and lung disease. [11] Oxidative stress is caused by free radicals, and mitochondria are known as the original location for free radical's generation. [12] When cellular quality alternates, oocyte and follicular cells lose their normal function. Given what was said and also that the production of primordial follicles during embryonic development in mammals has been a localized phenomenon and takes place due to ovarian indicators and germ cell, and also having in mind that continued follicular growth is more affected by hypothalamic and pituitary hormones, we can explain

the observed reduction in the number of primordial, early and growing follicles, and on the other hand this significant reduction (which for primordial follicles is the maximum) as such that (because in our experience significant alternation in pituitary hormone levels has been observed), FSH concentrations was observed to be increased significantly in experimental groups in compare with control group, and based on a research conducted by Hemayatkah Jahromi and colleagues in 2008, concentration of this hormone in mature male Balb/c mice strain was observed to be reduction, which is in contrary with what we have achieved in this study. This can happened because of free radicals and lipid per oxidation (1 captopril) which causes histological changes and thus interferes with hormones secretion. Obviously, the increase in atretic follicles due to a prevention in follicles continued growth or their development (for the mentioned reasons) can be quite reasonable.

As mentioned, a significant increase in the number of Graafian follicles in experimental groups, compared with the control group, has been observed. This phenomenon may be occurring for two reasons: either Paraquat causes more follicles (compared to normal mode) turn in to Graafian follicles, or a disorder in ovulation process increases the number of Graafian follicles. Given the hormonal mechanisms in rat estrous cycles, based on our experience, each of the above reasons may cause significant increase in the number of Graafian follicles. In addition, the observed significant reduce in the number of CL can also indicate the probable affected ovulation. Although no other study on the effects of Paraquat on follicular cells of Wistar rat has been done yet, but the result of experiences of Belford (1991) and Alex (1996) on the atrophy effect of Paraquat on Balb/C

mices strain ovaries and testis, also indicates oocytes and follicles reduction in animals. Actually corpus luteum is the remaining of follicular cells after ovulation. So if the ovulation rate of rats treated with Paraquat is reduced, obviously the number of CL should also reduce. This conclusion (significant decrease in the number of CL in experimental groups) is consistent with a significant reduction in blood Progesterone. Results showing reduction in diameter of the corpus luteum matches the results showing reduction in number of their cells. Hemayatkhah Jahromi concluded that these toxins damage cell proteins which lead to cell cytoplasm shrinkage. Reduction of corpus luteum diameter can be due to either reduction in cell numbers or their cytoplasm shrinkage. Based on results obtained in this study, Graafian follicle diameter and granulosa layers thickness and follicular sheath decreased significantly in experimental groups, compared with control group. Given that Paraquat affects DNA structure and cellular proteins which can alternate cell function, [12] and also considering the possible effects of Paraquat to alternate the natural gonadotropin concentration during injection period, [13] thus it can be concluded that with abnormal development of follicular cells and reduce in granulosa layer thickness and follicular sheath, estrogen secretion also reduces (decreased estrogen levels have been observed in our experiments) and this reduction exacerbates granulosa cells growth. As you know follicular sheath development is directly influenced by indicators secreted from granulosa layer and thus reduced effect of granulosa layer can also influence the growth of follicular sheath. Obviously, by reducing the number of follicular cells and granulosa layer thickness, the diameter of Graafian follicles also reduces significantly.

As noted above, the cellular damage caused by herbicides, can be developed for different reasons. But these damages are mainly caused by affecting the structure and function of DNA. [12] Therefore, these groups of herbicides have Alkylation property so they can influence DNA. They also have electrophilic characteristics that can affect cell proteins and their nuclei. Thus they can become the natural characteristics of oocyte cell (based on results obtained in this study).

Paraquat effects the results of FSH and LH levels in progesterone and estrogen groups in ovarian blood and results from this study suggest that Paraquat has histological effects on ovary. While gonadotropin hormones are secreted from pituitary, there is no research available about the effects of Paraquat on pituitary tissue in female genders and on the other hand, ovarian hormones through positive and negative feedbacks, affect pituitary gonadotropin secretion cycle during estrous periods (which of course the main role of hypothalamus should not be ignored). Given our experience about diameter reduction of the corpus luteum and also reduction the

number of its constituent cells, the significant reduction in progesterone hormone is justified. Similarly, the results of these experiments about thickness reduction of granulosa layer and follicular sheath, clearly confirm the significant reduction in estrogen levels.

According to the results of this study it can be said that Paraquat herbicide can affect female rat reproductive indicators destructively. Perhaps these effects may also be generalized to humans in a less subtle way, but in this case usage and the amount of usage of this herbicides as well as level of exposure is very important, so in generalizing these findings to humans care must be taken and possible experiments should be done.

Reference

1. Ghazi Khonsari Mahmoud, Maghsoud Shirin, Sotude Masoud, Shakiba Behnam, Mohammadi Gorgani Ali, 2004. Azar Partou, the effect of Captopril to prevent pulmonary fibrosis induced by Paraquat: role of nitric oxide, Department of Pharmacology (Poursina).
2. Lambert, C.E., S.C. Bondy, 1989. effects of MPTP, MPP+ and paraquat on mitochondrial potential and oxidative stress. *Life Sci.*, 44(18): 1277-84.
3. Rakhshani, E., A.A. Talebi, A.H. Taheri, 2006. Principles of Toxicology Agricultural. Publications dictionary, pp: 156- 177. [text in persian]
4. Taylor, N.L., D.A. Day, A.H. Millar, 2002. Environmental stress causes oxidative damage to plant mitochondria leading to inhibition of glycine decarboxylase. *J Bio chem.*, 277(45): 42663.
5. Brealy, C.Y., G.H. Walker, B.C. Bladwin, 1980. (A) Esterases activities in relation on the different toxicity of primiphos- methyl to birds and mammals. *Pestic sci.*, 11: 546-554.
6. Rumiza, A.R., O. Khairul, I.I. Mohd, Z. Rajamuhamad, A.H. Rogayah, 2008. Determination of malathion levels and the effect of malathion on the growth of *Chrysomya megacephala* (Fabricius) in malathion- exposed rat carcass. *Trooical biomedicine.*, 25(3): 184-190.
7. Corasaniti Neurotoxic, M.T., 1992. Effects Induced by Intracerebral and Systemic Injection of Paraquat in Rats.
8. Hideaki Matsumori and *et al.* 1984. Acute Toxic Effects Of Paraquat On Ultrastructure Of Rat Liver. *Pathology International.*, 34(3): 507-518.
9. Hemayatkhah Jahromi Wahid, Parivar Kazem, Baha al-Din Amin Ullah, 2008. Kafilzadeh Farshid. Effects of the Paraquat herbicide on histological changes in testis, reproductive, spermatogenesis process and pituitary hormones

- gonad in Balb/C mice strains, Iranian Journal of Biology, 21(3): 527-535.
10. Morán, J.M. and et al., 2010. Effect of paraquat exposure on nitric oxide-responsive genes in rat mesencephalic cells. Nitric Oxide., 23(1): 51-9.
 11. Scheffler, I.E., 2000. A century of mitochondrial research: achievements and perspectives. Mitochondrion, 1(1): 3-31.
 12. Cadnes, E., K.J. Davies, 2000. Mitochondrial free radical generation, oxidative stress, and again. Free radic boil med, 29(3-4): 222-230.
 13. Balford, A.U., 1991. Anderson A.Oncogenicity study of paraquat in rats. Toxiol., 51(3): 61-67.